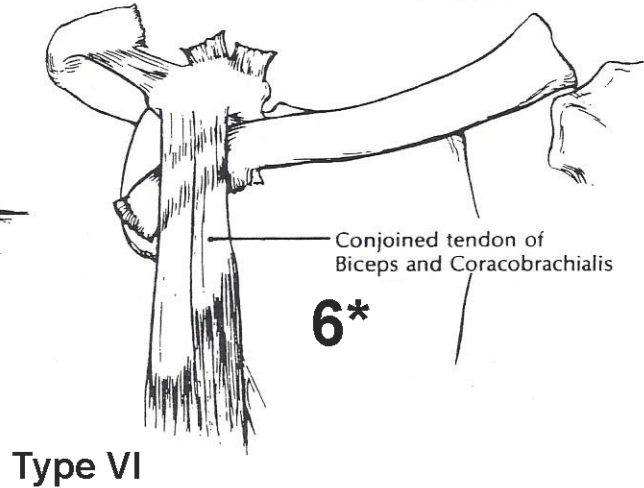
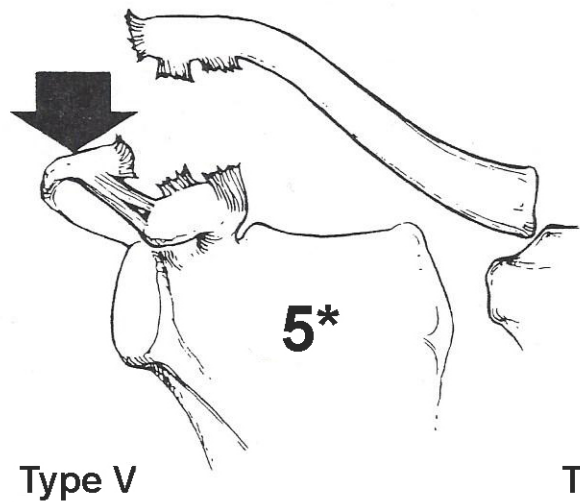
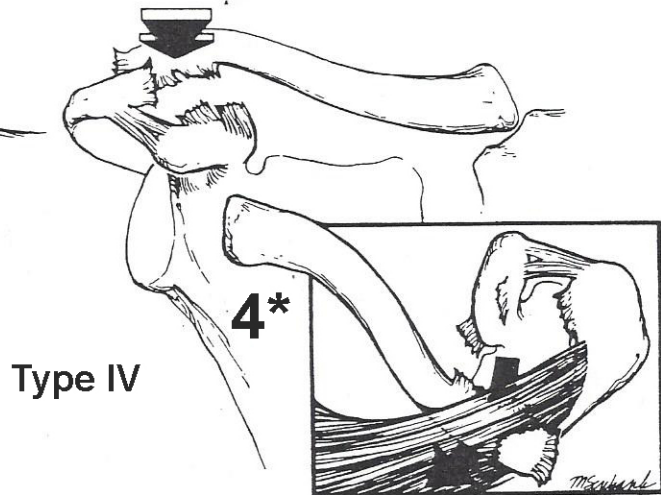
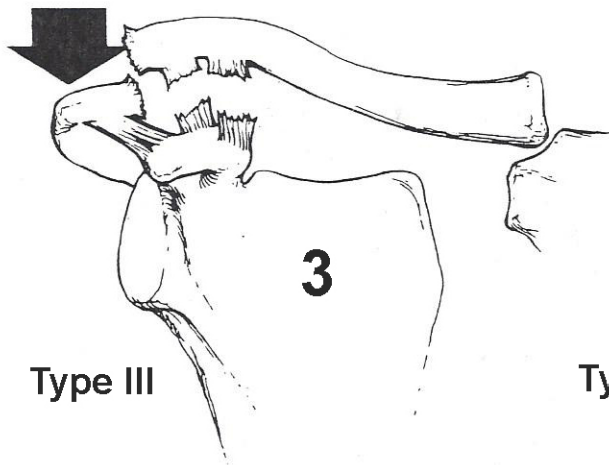
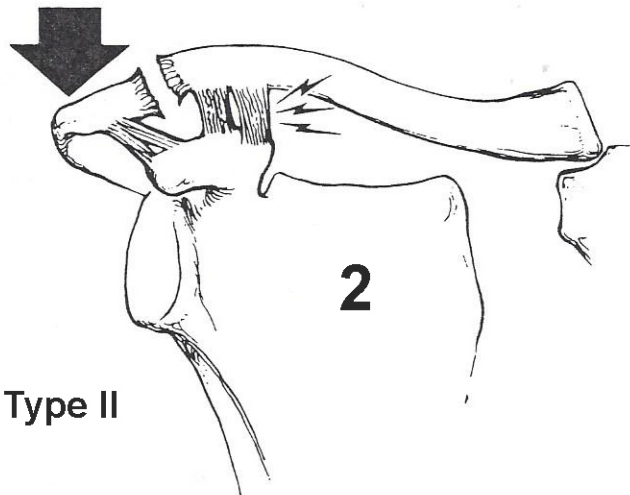
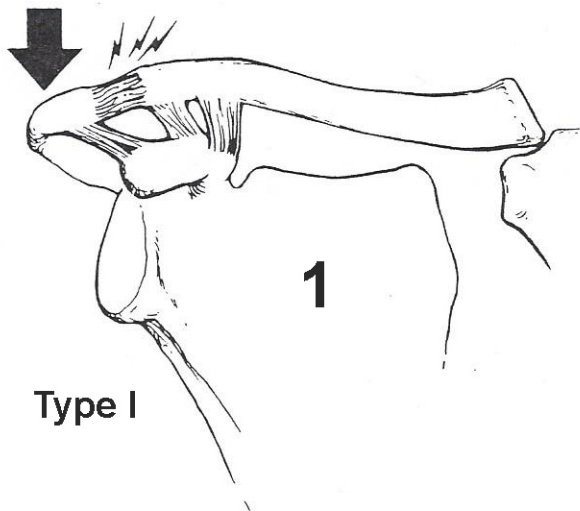


Acromioclavicular (A-C) Separations



***Operations are usually done on types 4, 5, & 6.**