

The Rotator Cuff-Deficient Arthritic Shoulder: Diagnosis and Surgical Management

Craig A. Zeman, MD, Michel A. Arcand, MD, Jeffery S. Cantrell, MD,
John G. Skedros, MD, and Wayne Z. Burkhead, Jr, MD

Abstract

The symptomatic rotator cuff-deficient, arthritic glenohumeral joint poses a complex problem for the orthopaedic surgeon. Surgical management can be facilitated by classifying the disorder in one of three diagnostic categories: (1) rotator cuff-tear arthropathy, (2) rheumatoid arthritic shoulder with cuff deficiency, or (3) degenerative arthritic (osteoarthritic) shoulder with cuff deficiency. If it is not possible to repair the cuff defect, surgical management may include prosthetic arthroplasty, with the recognition that only limited goals are attainable, particularly with respect to strength and active motion. Glenohumeral arthrodesis is a salvage procedure when other surgical measures have failed. Arthrodesis is also indicated in patients with deltoid muscle deficiency. Humeral hemiarthroplasty avoids the complications of glenoid loosening and is an attractive alternative to arthrodesis, resection arthroplasty, and total shoulder arthroplasty. The functionally intact coracoacromial arch should be preserved to reduce the risk of anterosuperior subluxation. Care should be taken not to "overstuff" the glenohumeral joint with a prosthetic component. In cases of significant internal rotation contracture, subscapularis lengthening is necessary to restore anterior and posterior rotator cuff balance. If the less stringent criteria of Neer's "limited goals" rehabilitation are followed, approximately 80% to 90% of patients treated with humeral hemiarthroplasty can have satisfactory results.

J Am Acad Orthop Surg 1998;6:337-348

localized shoulder arthritis associated with a large swelling about the shoulder, rotator cuff tear, biceps tendon rupture, and erosion of the superior portion of the humeral head, acromion, and distal clavicle. In his classic 1934 text, Codman described the case of a 51-year-old woman who had sustained a traumatic rotator cuff tear 6 years prior to surgery. During the operation he found, in addition to the large cuff defect, humeral head roughening, glenoid obliteration, intra-articular loose bodies, severe atrophy of the surrounding musculature, and a large fluid accumulation. He believed that these changes were the final stages of a chronically neglected large rotator cuff tear.

The patient with a symptomatic rotator cuff-deficient, arthritic glenohumeral joint poses a complex problem for the orthopaedic surgeon. Although this condition has been recognized since the early 19th century, there is no consensus on its management.¹⁻⁸ One of the difficulties is the diverse clinical presentation of patients with this disorder: some have rotator cuff-tear arthropathy (RCTA), as defined by Neer et al¹; others have end-stage rheumatoid arthritis (RA) or degenerative arthritis with cuff tears. Different surgical solutions may be required for each presentation.⁹ The surgeon

must also deal with osteopenic bone, severe soft-tissue contractures, and atrophied muscles. It may be impossible to repair the cuff defect. Consequently, many of the patients who come to surgery are treated with prosthetic arthroplasty with the recognition that only limited goals are attainable, particularly with respect to strength and active motion.^{1,7,9-11}

History

Between 1830 and 1860, Smith and Adams described several cases of

Dr. Zeman is in private practice in Oxnard, Calif. Dr. Arcand is in private practice in Norman, Okla. Dr. Cantrell is in private practice in Lewisville, Tex. Dr. Skedros is in private practice in Ogden, Utah. Dr. Burkhead is Clinical Associate Professor of Orthopaedic Surgery, University of Texas Southwestern Medical School, Dallas; and is in private practice with W. B. Carrell Memorial Clinic, Dallas.

Reprint requests: Dr. Zeman, W. B. Carrell Memorial Clinic, 2909 Lemmon Avenue, Dallas, TX 75204.

Copyright 1998 by the American Academy of Orthopaedic Surgeons.

More than a century later, Burman and co-workers described cases of recurrent spontaneous hemorrhage into the subdeltoid bursa in elderly patients with supraspinatus tendon tears and glenohumeral arthritis. In 1968, DeSeze called this condition *l'épaule sénile hémorragique* ("hemorrhagic shoulder of the elderly"). In 1977, Neer introduced the term "cuff-tear arthropathy" to describe findings associated with a chronic full-thickness rotator cuff tear, which include restricted shoulder motion, erosions of the osseous structures of the shoulder, and an arthritic, osteopenic, and collapsed humeral head.¹ In the early 1980s, Halverson et al^{12,13} described the "Milwaukee shoulder syndrome," which is in many ways similar to RCTA.

Types of Rotator Cuff Problems in Arthritic Shoulders

Surgical management of a rotator cuff-deficient arthritic shoulder can be facilitated by assigning it to one

of the following diagnostic categories: (1) RCTA, (2) degenerative arthritic (osteoarthritic) shoulder with cuff deficiency, and (3) rheumatoid arthritic shoulder with cuff deficiency. Categorization is based on specific clinical, radiographic, and laboratory findings. These designations help the surgeon anticipate the quality of tissues, the natural history of the disease, and the ultimate surgical outcome.

Rotator Cuff-Tear Arthropathy

In a 1983 landmark review article, Neer et al¹ expounded on Neer's original description of RCTA. Because RCTA was found not to be associated with degenerative arthritis in other joints, they suggested that a massive rotator cuff tear is the initial event in the pathogenesis. They also described mechanical and nutritional factors that may precipitate development of RCTA (Fig. 1).

Mechanical Factors

The concept of "force couples" in the shoulder emphasizes the critical nature of mechanical factors in the dynamic stability of the gleno-

humeral joint.¹⁴ For example, the glenohumeral joint is balanced anteriorly and posteriorly by the subscapularis, infraspinatus, and teres minor. Most large rotator cuff tears extend posteriorly into the infraspinatus and teres minor, leaving the subscapularis unbalanced. Due to unbalanced force couples, volitional attempts to elevate and/or rotate the arm can produce destructive forces in the glenohumeral joint. A deficient cuff may allow excessive upward migration of the humeral head, resulting in abrasion and erosion of the superior glenoid, acromioclavicular joint, and acromion. Because only about 4% of shoulders with full-thickness rotator cuff defects progress to RCTA,¹ mechanical factors do not appear to be wholly responsible for the pathologic features of RCTA described by Neer.

Nutritional Factors

As in other diarthrodial joints, the articular surfaces of the shoulder receive nutrition from synovial fluid. A full-thickness rotator cuff tear violates the closed joint space,

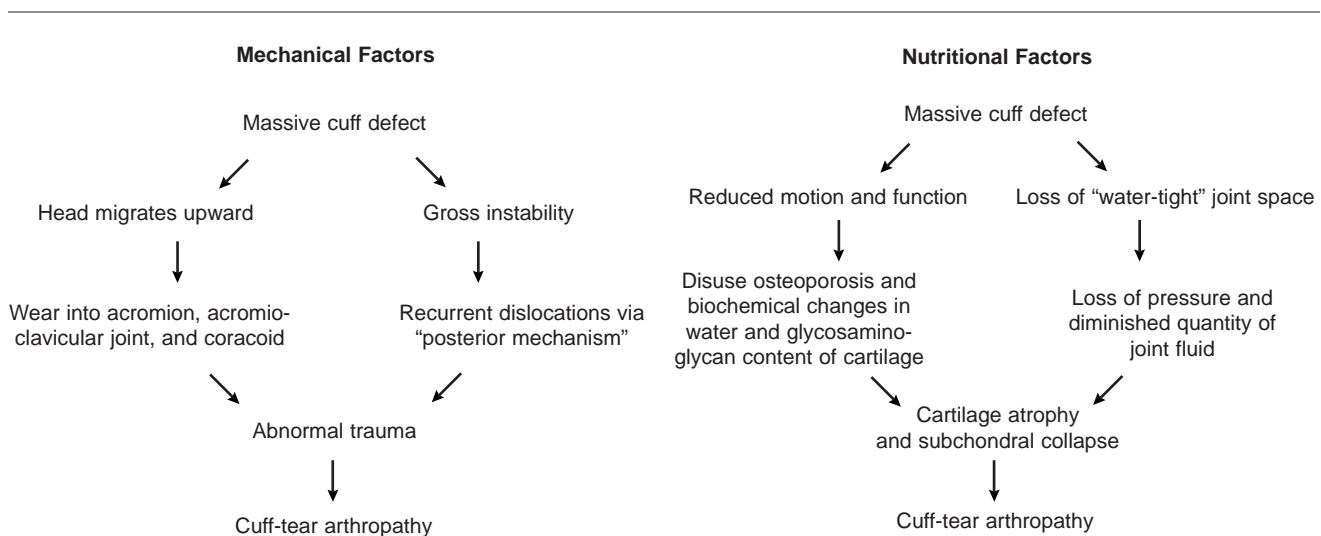


Fig. 1 Mechanical factors (left) and nutritional factors (right) that contribute to joint destruction in RCTA, according to Neer et al.¹ (Adapted with permission from Neer CS II, Craig EV, Fukuda H: Cuff-tear arthropathy. *J Bone Joint Surg Am* 1983;65:1232-1244.)

allowing synovial fluid, with its nutrients and other biochemical constituents, to leak into the subdeltoid and subacromial spaces and surrounding soft tissues. In addition, pain leads to shoulder inactivity, which reduces the delivery of synovial nutrients and produces disuse osteopenia and joint stiffness. All of these factors contribute to articular cartilage destruction.

Inflammatory Factors

The rheumatology literature contains an abundance of clinical cases that appear grossly similar to RCTA.¹²⁻¹⁷ However, explanations of the etiology of these conditions emphasize biochemical factors, differing from Neer's emphasis on deficient cartilage nutrition and marked glenohumeral instability. In many of the cases reported by rheumatologists, crystal-induced inflammation is considered to be the cause of destruction. Halverson and co-workers identified basic calcium phosphate crystals (BCPs), such as hydroxyapatite, in the synovial tissue and fluid of shoulders with apparent inflammatory arthropathy.^{12,13} They hypothesized that the crystals are formed in diseased synovium and articular cartilage and then released into the synovial fluid. Subsequent phagocytosis of these crystals by macrophages induces a phlogistic response that destroys the rotator cuff tendon and articular cartilage. As the tissue is damaged, additional crystals are released, resulting in a vicious circle. This interpretation implies that the cuff is not torn traumatically in RCTA but is severely degenerated and characterized by a 5-cm or larger defect.²

In 1985, Dieppe and Watt¹⁶ reviewed the role of crystal deposition in the pathogenesis of osteoarthritis (OA). They noted that BCP crystals have been found in osteoarthritic joints, neuropathic joints, and joint tissue of healthy elderly patients and that apatite crystals in

particular seem to occur in the more destructive atrophic situations. Consequently, they speculated that BCP crystals may be a product of articular surface wear, and that the crystals are produced by processes that are secondary to joint destruction and are not the inciting cause. They proposed crystal deposition as an opportunistic event in OA, with the joint damage predisposing to deposition, and the deposits in turn modifying the underlying disease. If this interpretation is correct, Milwaukee shoulder syndrome may be a localized form of erosive OA.^{16,17}

Osteoarthritic Shoulder With Cuff Tear

In patients with an osteoarthritic shoulder and a cuff tear, the primary diagnosis is OA, and the associated cuff tear is traumatic or attritional.^{2,18} Occasionally, hypertrophic arthritis develops after a cuff tear or repair or after a shoulder replacement.

Rheumatoid Arthritic Shoulder With Cuff Tear

Patients with RA in the shoulder and a cuff tear typically have systemic symptoms, physical signs, and radiographic and laboratory findings consistent with RA. The radiographic appearance is similar to that of RCTA, albeit commonly with more destruction.¹⁸ Extensive rotator cuff tearing is not usual in the shoulder affected by RA.¹⁸

Diagnosis

History and Physical Examination

Patients with cuff-deficient, arthritic shoulders are typically elderly (seventh decade or older) and female. Most commonly, it is the dominant extremity that is involved. Patients usually present with a long history of progressively

increasing pain that is worse at night and is intensified by glenohumeral motion. They also report loss of active shoulder motion. The observation by Neer et al¹ that 10 of 26 patients with RCTA had not received antecedent corticosteroid injections diminishes their importance as an etiologic factor.

Patients with OA and rotator cuff tears also relate a history of progressive pain and stiffness. It is not uncommon for these patients to relate an acute traumatic event followed by increased shoulder weakness and symptoms. Patients with rotator cuff tears and RA generally have a long history of polyarthritis and medical treatment for their systemic disease. They may have pain in other joints of the hands, wrists, elbows, hips, or knees.

In patients with RCTA, atrophy of the supraspinatus and infraspinatus muscles and weakness of external rotation and abduction are typical physical findings on clinical examination. Active and passive attempts to move the shoulder through a functional range are limited by weakness, pain, and stiffness. This is most apparent in external rotation and abduction. A rupture of the biceps tendon may be detected. A large shoulder swelling, or "fluid sign," which results from chronic, excessive fluid pressure in the subacromial bursa, may also be noted (Fig. 2). Aspiration of the fluid, which may be bloody or blood-streaked, followed by cortisone injection, is an excellent temporizing measure that can be undertaken in an attempt to avoid surgery; however, recurrence after aspiration is common.

Patients with either RA or OA can have mild swelling, but this is usually synovial-tissue thickening rather than fluid that can be aspirated. These patients may also have physical findings involving other joints, such as deformity, contractures, or instability.

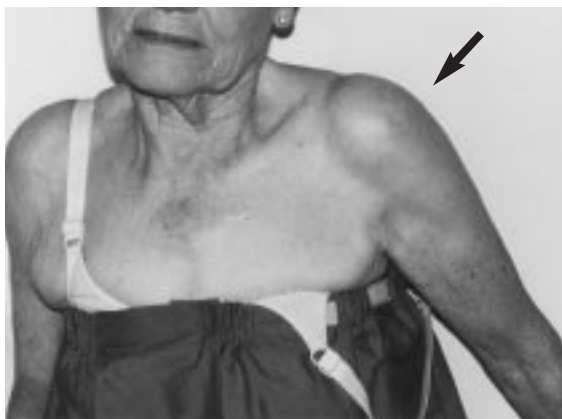

Fig. 2 The fluid sign is seen as a swelling (arrow) on the anterior aspect of this patient's shoulder. This is caused by fluid bulging from the glenohumeral joint through a large chronic cuff tear and into the enlarged subacromial bursa. Less commonly, fluid in the subdeltoid bursa can be associated with primary bursal involvement in RA.¹⁸

Imaging

There are a number of characteristic plain-radiographic findings of RCTA (Fig. 3). Erosion of the proximal humerus may be so extensive that the humeral head is worn beyond the surgical neck. Axillary lateral radiographs may reveal a fixed anterior or posterior glenohumeral dislocation.

Radiographs of osteoarthritic shoulders typically show subchondral sclerosis, humeral head osteophytes, glenoid osteophytes, and posterior erosion of the glenoid.¹⁸ In contrast to RA and RCTA, osteopenia is not characteristic of conventional OA. Unlike osteoarthritic shoulders, rheumatoid shoulders are characterized by relatively symmetrical juxta-articular erosion and relatively minimal subchondral sclerosis and osteophytosis.¹⁸

Patients with cuff deficiency require extra preoperative, intraoperative, and postoperative decision making. Although magnetic resonance imaging is not necessary for the routine preoperative workup of patients with straightforward OA and obvious clinical and radiologic findings indicative of a full-thickness rotator cuff tear, it may be useful in patients with physical findings that are difficult to interpret (e.g., those who cannot do a lift-off or belly-press test because of pain and

motion loss). Because cuff tears may have unexpected configurations and sizes and the cuff tissue may be of poor quality, the surgeon must be prepared to use alternative methods (e.g., autografts, allografts, or tendon transfers) in reconstruction or repair. These intraoperative decisions are facilitated by preoperative knowledge gained with magnetic resonance imaging.

Differential Diagnosis

The radiographic appearance of glenohumeral joints in patients with metabolic arthritis resembles that in patients with OA; however, the rotator cuff is usually intact. In some advanced cases, the radiographic findings can be similar to those seen with advanced RCTA. Blood and joint-fluid chemistries and synovial biopsy can help confirm a diagnosis of gout, pseudogout, hemochromatosis, and other types of metabolic arthritides.

Patients with septic arthritis are often debilitated due to a generalized disease process such as RA.¹⁹ In the absence of fever and an elevated white blood cell count, diagnosis depends on a high level of suspicion and the findings from joint aspiration and culture. If an effusion is present, it is warm, in contrast to the cool effusion of RCTA.

Patients with Charcot (neuropathic) joints and osteonecrosis usually have intact rotator cuffs. Clinical workup may ultimately reveal an underlying cause, such as corticosteroid use, alcohol abuse, tabes dorsalis, or syringomyelia.

Patients with a history of hemophilia and numerous hemarthroses may also have hemophilic arthropathy. Radiographs of shoulders with advanced disease may resemble those of shoulders with RA or, less commonly, OA. Dark pigmentation of the joint tissues is apparent on gross examination, and histologic examination of joint cartilage reveals chondrocytes with intracellular iron deposits.

Indications for Surgery

The main indication for surgical management is unremitting pain that has proved resistant to a trial of nonoperative measures, including

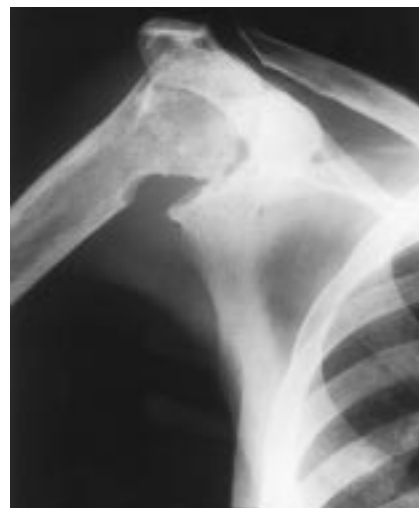


Fig. 3 Anteroposterior radiograph shows RCTA in the right shoulder of a 77-year-old man. The shoulder is in maximum active abduction. In addition to humeral head collapse, findings include periarticular osteopenia, reduced acromiohumeral distance, and erosions of the glenoid, acromion, and acromioclavicular joint.

rest, oral analgesics and nonsteroidal anti-inflammatory medications, corticosteroid injections, fluid aspirations, and gentle range-of-motion exercises. Additional considerations, such as patient age, activity level, job requirements, and general health, are extremely important in individualizing a treatment plan. The integrity of the contralateral rotator cuff should also be assessed, as this may be important in planning postoperative rehabilitation. Patients who use canes or are confined to wheelchairs may, during the first few postoperative months, apply increased stresses to the contralateral shoulder; a course of preoperative stretching before a prosthetic arthroplasty may improve postoperative function.²

Surgical Options

Shoulder Arthrodesis

Many patients with a cuff-deficient, arthritic shoulder have poor general health and are at increased risk for major surgical complications. Shoulder arthrodesis is an extensive operation that, when combined with spica immobilization, may not be well tolerated by these individuals.^{10,19,20} In addition, because of poor bone stock, these patients may have a higher failure rate than younger individuals. However, with the use of internal fixation, autogenous and allogeneic bone graft material, and aggressive medical management, glenohumeral arthrodesis is a viable option, especially in the patient with RCTA, an irreparable cuff defect, and a deficient anterior deltoid who has undergone multiple procedures.²⁰ However, it is infrequently the optimal surgical option in this setting.^{19,20}

Resection Arthroplasty

Resection arthroplasty is not recommended for the patient with a

cuff-deficient arthritic shoulder. It typically produces a flail shoulder that leaves the patient even more disabled because deltoid function is often deficient as well. Inferior instability and brachial-plexus traction neuritis are common and contribute to the severely compromised shoulder biomechanics.

Constrained Shoulder Replacement

In 1991, Laurence²¹ reported on the use of polyethylene cups and large stainless-steel heads that snap-fit together to form a constrained construct. After resection of the superior two thirds of the glenoid, screws and bone cement are used to fix the cup into this region and into the coracoid and acromion. Seventy-one shoulders in 66 patients were followed up for an average of 6.8 years. All of the patients apparently had large rotator cuff defects. The remaining distal cuff tendons were surgically transected with the tuberosities and reattached more distally after placement of the prosthetic components. There was complete relief of pain in 22 patients, only minor discomfort in 35, and moderate pain in 9. Two shoulders were considered surgical failures, and 3 required revision surgery for loosening (2 after trauma). Active use of the arm was regained by 56 patients (85%), and 26 (40%) returned to gainful employment.

Once considered a solution for the patient with a cuff-deficient arthritic shoulder, constrained shoulder replacement created a whole new set of complications.¹⁸ A theoretical advantage of this surgical option is that it provides the deltoid with a stable fulcrum on which to move the humerus when there is impairment of the normal force couple between the cuff and the deltoid due to cuff insufficiency. However, constrained shoulder replacement, which is not approved

by the US Food and Drug Administration, is not considered appropriate treatment because the design produces excessive interface stresses, which can lead to rapid loosening, implant dissociation, and bone and implant fracture.^{6,18,22}

Shoulder Bipolar Arthroplasty

Swanson and Swanson⁸ pioneered the use of shoulder bipolar arthroplasty for treating arthritic shoulders with loss of the force-couple balance required to hold the humeral head in the glenoid during abduction. Theoretical advantages provided by the large head of this arthroplasty include the following factors: (1) smooth concentric total contact for the entire shoulder joint cavity; (2) reduction of force concentration over any one contact area and, therefore, decreased resistance to movement; (3) longer moment arm between the fulcrum and the muscle insertion, increasing the efficiency of muscle pull; and (4) prevention of impingement by the greater tuberosity against the acromion.

Lee and Niemann²³ reported on the results of shoulder bipolar arthroplasties performed on 14 patients, 13 of whom had irreparable large rotator cuff tears. Two groups were studied: 7 patients with RA who underwent a primary shoulder arthroplasty and 7 patients who underwent a secondary reconstructive procedure. No rotator cuff reconstruction was performed. The patients with RA all had good pain relief and reported satisfaction with the results of surgery. In contrast, the patients in the secondary reconstruction group had only fair pain relief, and only 4 of the 7 were satisfied with their results. The RA group had a nearly threefold greater increase in range of motion than the secondary reconstruction group. The authors concluded that bipolar arthroplasty was a good choice for treating

patients with RA and massive cuff tears, but one disadvantage was the large amount of bone resection required. Fewer complications occurred when the subacromial arch was intact. If the cuff was repairable, the investigators performed a standard Neer-type hemiarthroplasty or total shoulder arthroplasty (TSA).

Nonconstrained Total Shoulder Arthroplasty

In 1982, Neer et al⁹ reported on the results of nonconstrained TSA in 194 shoulders in patients treated for various diagnoses. Follow-up was from 24 to 99 months. Rotator cuff-tear arthropathy was found in 16 shoulders. Two patients (3 shoulders) had OA and a cuff defect (size not reported); both patients were paraplegic as a result of poliomyelitis. Twelve patients had large cuff tears and RA; 17 additional patients with RA had small cuff tears that were easy to repair. In the RCTA group, all but 1 patient had a successful result with "limited goals" rehabilitation. The 2 patients in the OA group were satisfied with their postsurgical results. Seven of the patients with RA and massive cuff tears had successful results on the basis of limited-goals rehabilitation criteria. The remaining 22 RA patients had satisfactory to excellent results with a full exercise rehabilitation protocol. Although lucent lines developed around the glenoid component in nearly 30% of each group, symptomatic loosening did not occur.

In 1984, Cofield¹⁰ reported the results of 73 TSAs in 65 patients who had RA, OA, or posttraumatic arthritis and were followed up for an average of 3.8 years. Of the 31 shoulders with OA, 3 had "minor" and 3 had "major" rotator cuff tears (major tears were at least as long as the breadth of the supraspinatus tendon). Of the 29 shoulders with RA, 1 had a minor cuff tear, and 6

had major tears. Four longitudinally torn supraspinatus tendons were repaired by simple suturing. Of the 9 shoulders with major rotator cuff tears, 6 were repaired by suturing tendon directly to the cancellous bone of the proximal humerus. The major tears in the remaining 3 shoulders were repaired with fascia lata grafts. Five of the rotator cuff repairs had failed by the time of the last reported follow-up, and 1 patient had severe pain. The amount of active abduction that was achieved postoperatively was clearly related to the condition of the rotator cuff at surgery. When no complications occurred, results were predictably good. Cofield concluded that these results were superior to those obtained with shoulder fusion in patients with similar shoulder conditions.^{10,19}

Hawkins et al⁵ reported the results in 65 patients treated with TSA for OA and RA who were followed up for an average of 36 months. Twenty-one patients, most in the RA group, had rotator cuff tears, and all but 1 patient had satisfactory repair of the rotator cuff. The results were satisfactory in 90% of the shoulders, with no difference being noted between OA and RA patients.

Barrett et al²² reported the results of TSA in 50 shoulders of 44 patients who were followed up for an average of 3.5 years. Nine shoulders had a tear of the rotator cuff. Three tears were less than 5 cm and were repaired; repair and/or reconstruction was attempted in the others, but all of the results were considered suboptimal. Of the 6 patients with painful shoulders at follow-up, 4 had glenoid component loosening; at the time of the original procedure, all 4 patients had had a massive tear of the rotator cuff. Two of these patients underwent revision with a hemiarthroplasty, 1 had a resection arthroplasty, and 1 elected no fur-

ther surgery. The authors theorized that in some cases the superiorly subluxated humeral head eccentrically loaded the glenoid component, ultimately producing rocking and progressive loosening of the glenoid component.

Franklin et al⁶ reported an association between glenoid loosening and rotator cuff deficiency with proximal humeral migration. Of 14 patients with rotator cuff deficiency, 7 demonstrated glenoid component loosening. None of the 16 patients with an intact cuff had a loose glenoid component. The amount of superior migration of the humeral component directly correlated with the degree of glenoid loosening. The authors emphasized that an intact, functional rotator cuff can reduce eccentric glenoid loading by centering the humeral head on the glenoid during dynamic shoulder motion.

Humeral Hemiarthroplasty

Marmor¹¹ reported the results of humeral hemiarthroplasty in 12 shoulders of 10 patients with RA followed up for an average of 4.5 years. Five of the 12 shoulders had a rotator cuff tear (size not specified). All patients eventually had good pain relief. One patient with significant pain required an acromioplasty after the initial procedure. All but 1 patient ultimately attained increased motion.

Arntz et al used humeral hemiarthroplasty as an alternative to glenohumeral arthrodesis for the cuff-deficient arthritic shoulder. In 1993 they reported the results in 18 shoulders in 16 patients followed up for 25 to 122 months.²⁴ Eleven patients had RCTA. A prerequisite for surgery was a functionally intact coracoacromial arch, providing secondary stability across the anterosuperior aspect of the humeral prosthesis. A smaller prosthetic head was used to avoid pain associated with excessive

tightness of the posterior capsule. Excessive shoulder tightness was also avoided by allowing 50% posterior subluxation of the humeral component on the glenoid fossa and 90 degrees of internal rotation of the abducted humerus. In all cases, the rotator cuff was not repaired because of poor tissue quality. At the final reported follow-up, 3 shoulders were pain-free, 8 shoulders were slightly painful, 4 shoulders were painful after activities that the patients described as not typical of daily use, and 3 shoulders were markedly painful and had to undergo revision procedures. Humeral component loosening was not seen.

In 1996, Williams and Rockwood²⁵ reported on the results of humeral hemiarthroplasty in 21 shoulders of 20 patients with irreparable rotator cuff defects and glenohumeral arthritis who were followed up for an average of 4 years. During subscapularis repair, they invariably achieved 30 degrees of external rotation. To achieve this degree of motion in 6 shoulders, the subscapularis was removed subperiosteally from the lesser tuberosity and reattached 1 to 2 cm more medially through holes drilled near the edge of the humeral osteotomy. In 2 patients with deficient subscapularis muscles, the upper 50% of the pectoralis major was transferred to the lesser tuberosity. To prevent posterior instability in patients with posterior erosion of the glenoid, the osteotomy was made in only 10 to 15 degrees of retroversion. Twelve shoulders were not painful, 6 were mildly painful, and 3 were moderately painful. Patients with moderate pain who had undergone previous operations stated that the recent surgery ameliorated their pain.²

When performing hemiarthroplasty on the cuff-deficient arthritic shoulder, especially in the setting of previously failed cuff surgery,

the surgeon often encounters an incompetent coracoacromial arch. Some authors have augmented the arch with bone graft. In 1991, Wiley²⁶ reported on four patients in whom severe superior humeral head subluxation developed after resection of the coracoacromial ligament. Three of the patients also underwent repair of a large to massive cuff tear. These four cases were selected to illustrate the potential complications of debriding the cuff without repair and the value of retaining the coracoacromial arch. Two patients had undergone humeral head replacement arthroplasty. Subsequent treatment of these patients included capsular release and bone grafting of the coracoacromial arch with a 7.5-cm-long piece of iliac-crest bone (Fig. 4). Postoperatively, both patients had significant pain relief.

In contrast to this method, Engelbrecht and Heinert²⁷ described the concept of augmenting the superior aspect of the glenoid with

bone from the humeral head (Fig. 5), so as to resist humeral head migration in the superior direction. Both this technique and that of Wiley seek to reestablish a stable fulcrum. The technique of Engelbrecht and Heinert seems to make better sense biomechanically, as it reestablishes the fulcrum closer to the original instant center of rotation.

In 1997, Field et al²⁸ reviewed the data on 16 patients who had undergone humeral hemiarthroplasty for RCTA. The surgical technique and component sizing (with use of a small humeral head) were similar to those described by Arntz et al.²⁴ All tears were massive and were debrided without an attempt at repair. The average age of the patients was 74 years (range, 62 to 83 years), and follow-up averaged 33 months (range, 24 to 55 months). With the use of Neer's limited-goals criteria, the results in 10 patients were rated as successful; those in 6, as unsuccessful. Of the 6 patients with unsuccessful

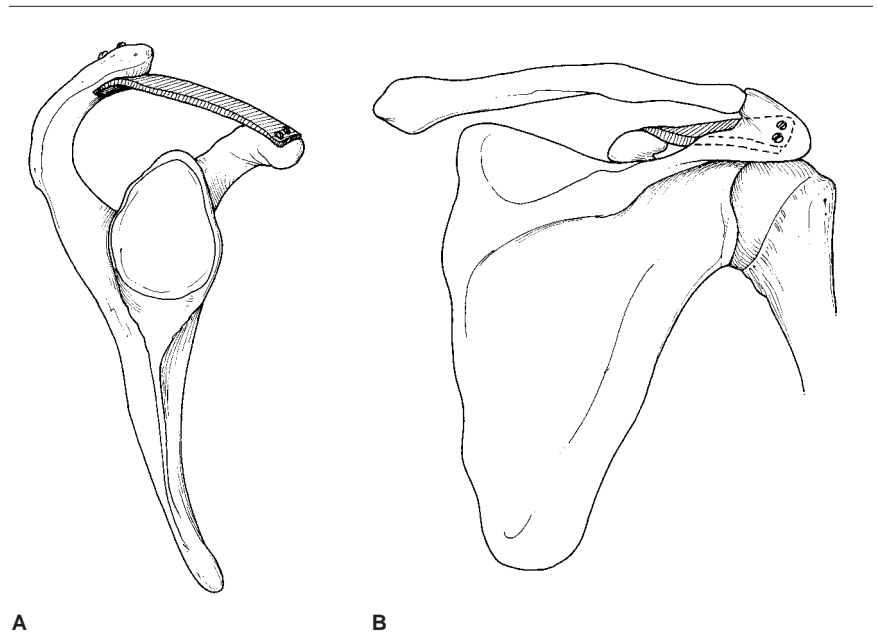


Fig. 4 Lateral-to-medial (A) and posteroanterior (B) views of a scapula showing an iliac-crest bone graft rigidly attached to the acromion and coracoid, serving to reconstitute a deficient coracoacromial arch.

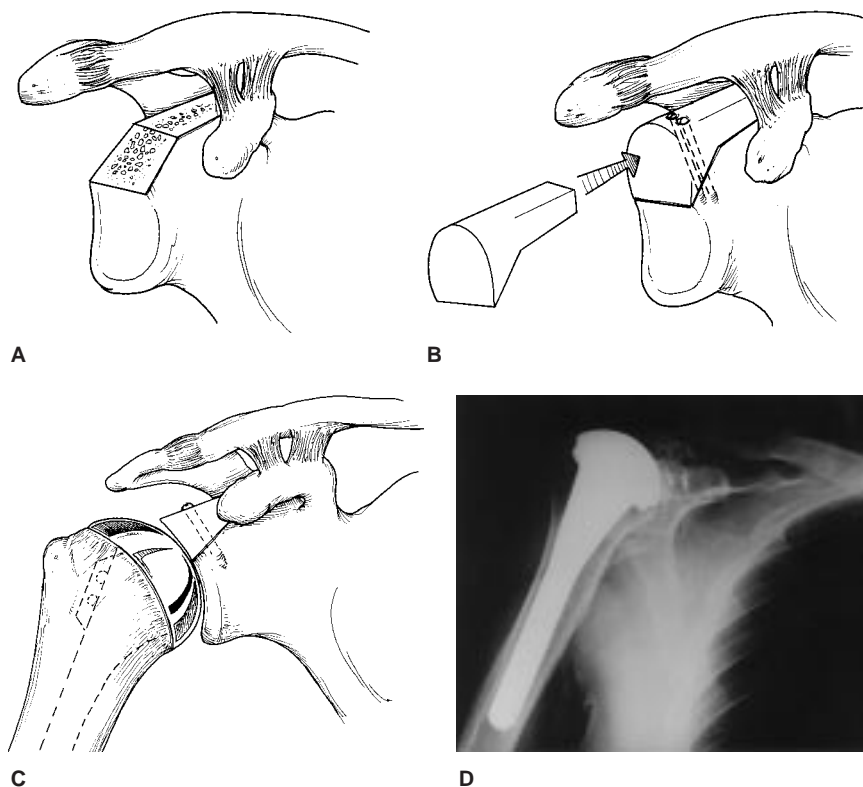


Fig. 5 A, Use of humeral head bone for grafting of a deficient superior pole of the glenoid serves to resist superior humeral migration. B, Placement of bone graft and fixation with screws. C, Topographic relationship of graft with prosthetic humeral head. D, Radiograph shows a graft in a 73-year-old man. Note the use of suture anchors for fixation into osteoporotic bone.

results, 4 had undergone at least one attempt at rotator cuff repair with acromioplasty before the index procedure, and 2 had deficient deltoid function after the rotator cuff surgery as a result of postoperative deltoid detachment. Also, 3 of these 4 patients who had previously undergone acromioplasty subsequently had anterosuperior subluxation after hemiarthroplasty. However, of the 12 patients with good deltoid function and an adequate coracoacromial arch, 10 had a successful result. This study illustrates that formal acromioplasty done in combination with repair of a torn rotator cuff may jeopardize the subsequent success of humeral hemiarthroplasty.

Humeral Hemiarthroplasty Versus Total Shoulder Arthroplasty

Lohr et al⁴ briefly reported the results of RCTA in 22 shoulders in 22 patients with RCTA who were treated with either nonconstrained TSA, semiconstrained (i.e., hooded glenoid) TSA, or hemiarthroplasty. The mean follow-up period was 4 years 7 months. The hemiarthroplasty group had the poorest results for pain relief. However, the nonconstrained and semiconstrained TSA groups had a high incidence of radiologic and clinical loosening of the glenoid component. The authors concluded that although RCTA is one of the most difficult-to-treat shoulder entities, every attempt should be made to repair

the rotator cuff. In their study, nonconstrained TSA yielded the best results.

In 1992, Pollock et al⁷ reviewed the results in 30 shoulders in 25 patients treated with either TSA (11 shoulders) or humeral hemiarthroplasty (19 shoulders) for glenohumeral arthritis with rotator cuff deficiency. Follow-up averaged 41 months. Seventeen arthroplasties were for RA or inflammatory arthritis, and 13 were for RCTA. Transposition of the subscapularis (Fig. 6) resulted in complete closure of superior rotator cuff defects in 15 shoulders and partial closure in 11. Four cuffs with massive defects could not be covered and were not reconstructed. Satisfactory results were achieved in all patients in the RA or inflammatory arthritis group and 11 of 13 in the RCTA group. All shoulders regained functional forward elevation and external rotation. Patient satisfaction was similar in the hemiarthroplasty and TSA groups, but the hemiarthroplasty group achieved greater postoperative range of motion. The authors concluded that hemiarthroplasty with attempted rotator cuff repair produced the best results in these patients.

A patient with OA and a small, easy-to-repair rotator cuff tear can usually be treated with a modular nonconstrained TSA. Severe bone loss in osteopenic patients generally requires fixation with polymethylmethacrylate. A deltopectoral approach is used. Many of these shoulders have osseous excrescences on the acromion and acromioclavicular joint arthritis, which can be dealt with in a standard fashion as long as the cuff is repairable. A slightly smaller humeral head or a tendency toward varus angulation during implantation will take pressure off the cuff repair. It is essential that 30 to 40 degrees of external rotation can be obtained

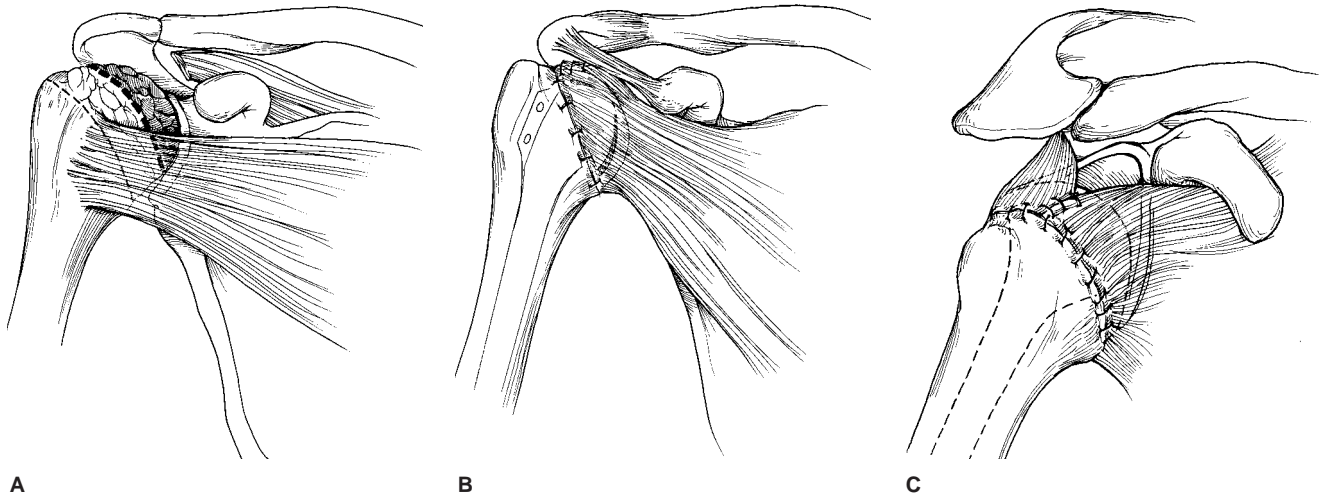


Fig. 6 A, Preoperative anteroposterior (AP) view of a right shoulder with a cuff tear and severe glenohumeral arthrosis. The broken line drawn obliquely across the proximal humeral head represents the direction of an osteotomy performed when there is an intact rotator cuff. The dotted line drawn obliquely across the more distal humeral head represents the more aggressive osteotomy used when performing an arthroplasty in shoulders with large, retracted rotator cuff tears. Postoperative AP (B) and oblique (superior-to-inferior) (C) views show use of a superiorly transposed subscapularis tendon to cover a large cuff defect; prosthetic humeral head has been recentered.

intraoperatively after repair of the subscapularis. Replacement of the glenoid is not recommended for patients with superior humeral head migration, as this finding is associated with a high incidence of glenoid loosening.

Some basic surgical principles should be emphasized before addressing specific details of this type of management. Protection of the axillary nerve is paramount, as contractures and joint deformities make it susceptible to intraoperative injury. The surgeon must have a thorough understanding of how to release joint contractures and safely mobilize the rotator cuff.²⁹ Mobilization may include (1) release of bursal adhesions from the subacromial and subdeltoid spaces, (2) release of the subscapularis from the capsule, (3) release of the contracted capsule from the glenoid labrum, (4) proximal mobilization of tendons,³⁰ (5) release or resection of the coracohumeral ligament, (6) rotator interval slide,³¹ and/or (7) release of the upper 1 cm of the pectoralis major to facili-

tate exposure for mobilization of the subscapularis or the entire pectoralis major insertion if transfer is required.²

Neer et al¹ have stated that in rare cases a supplemental posterior incision may be needed to adequately mobilize the posterior rotators. Various methods of subscapularis lengthening may also be necessary in these stiff shoulders. If the cuff tear is small and the subscapularis tendon is of good quality, the tendon can be dissected subperiosteally off the lesser tuberosity as close as possible to the bicipital groove. This tissue can then be reattached to the anteromedial aspect of the anatomic neck with the use of suture and drill holes. For patients with massive rotator cuff tears, internal rotation contractures, and good-quality subscapularis tendon, a coronal Z-lengthening procedure is utilized. The subscapularis is not routinely separated from the joint capsule. The surgical approach is determined on the basis of whether or not the subscapularis is intact.³²

Intact Subscapularis

Although many patients with an intact subscapularis have a negative lift-off test, they may have marked weakness with active forward flexion and external rotation. For these patients, a standard deltopectoral approach is appropriate. A more aggressive humeral osteotomy is also performed, which removes more bone than usual. The osteotomy follows a line extending laterally from approximately 1 cm above the lateral flare of the greater tuberosity to a point medially where, with firm manual downward traction on the arm, the humeral neck meets the inferior aspect of the glenoid. This satisfies three objectives: (1) it leaves an osseous margin to which the distal ends of the supraspinatus, infraspinatus, and subscapularis can be repaired; (2) it shortens the distance that the mobilized tendons must traverse; and (3) it centers the humeral head on the glenoid. Despite aggressive capsular releases inferiorly, the humeral head cannot be centered without this relatively large amount of bone resection.

When there is marked superior erosion of the glenoid, a burr is used to selectively remove bone from the inferior aspect of the glenoid until a superior shelf is created. The effective length of the subscapularis is increased by medializing the joint line, mobilizing the cuff, lowering the instant center of rotation, and using a smaller humeral head. These factors facilitate transposition of the subscapularis for covering large defects in the retracted supraspinatus tendon (Fig. 6). Preservation of the coracoacromial arch is extremely important for limiting anterosuperior migration. When the posterior glenoid is not eroded, the prosthesis should generally be retroverted more than usual (45 to 60 degrees), placing the greater part of the prosthetic head under the acromion. This maneuver ensures that, at the very least, the shoulder has captured-fulcrum mechanics¹⁴ (Fig. 7). Although not routinely obtained, a computed tomographic scan of both shoulders can be useful for comparing glenoid version in some patients³³; this information helps the surgeon to anticipate both the location and the amount of bone removal or augmentation that will be needed.

Deficient Subscapularis

If the patient has a positive lift-off test, the subscapularis is involved in the massive tear, and the patient has marked weakness with almost all active movements of the shoulder. In this situation, a superior approach, as described by Kessel,³⁴ is recommended; the acromial osteotomy facilitates increased exposure of the superior aspect of the glenohumeral joint. The acromion must be repaired accurately and securely. With an aggressive humeral osteotomy and reshaping of the glenoid with a burr, the resulting medialization of the glenoid usually allows repair of the subscapularis back to the lesser tuberosity and repair of the infraspinatus back to the greater tuberosity; however, the superior defect typically cannot be repaired. In our experience, use of humeral head bone to supplement the superior aspect of the glenoid has resulted in keeping the head centered in 3 of 5 patients followed up for more than 2 years (Fig. 5).

Deficient Deltoid

Even if the cuff defect is reparable or reconstructible, attempts at restoring motion or balancing force couples with prosthetic replacement

and soft-tissue reconstruction are fruitless if the anterior deltoid is deficient due to detachment or denervation. In this case, glenohumeral fusion with the use of pelvic reconstruction plates, autogenous and/or allogeneic bone graft, scalene block anesthesia, and postoperative management of medical problems or metabolic bone disease make this an attractive alternative even for patients in their late 70s or 80s.

Postoperative Management

Postoperative management begins with preoperative education of the patient and her or his family, emphasizing that pain relief is the primary goal of surgery, and realistic expectations for range of motion and strength are typically limited.¹ On the first or second postoperative day, patients are taught passive exercises, which are continued for at least 6 weeks. These exercises may be delayed for 3 weeks if subscapularis reattachment or lengthening was performed. Between 6 and 9 weeks, depending on the size of the cuff tear and tissue quality, gentle active motion is allowed in all planes. When the rotator cuff repair is tenuous, an

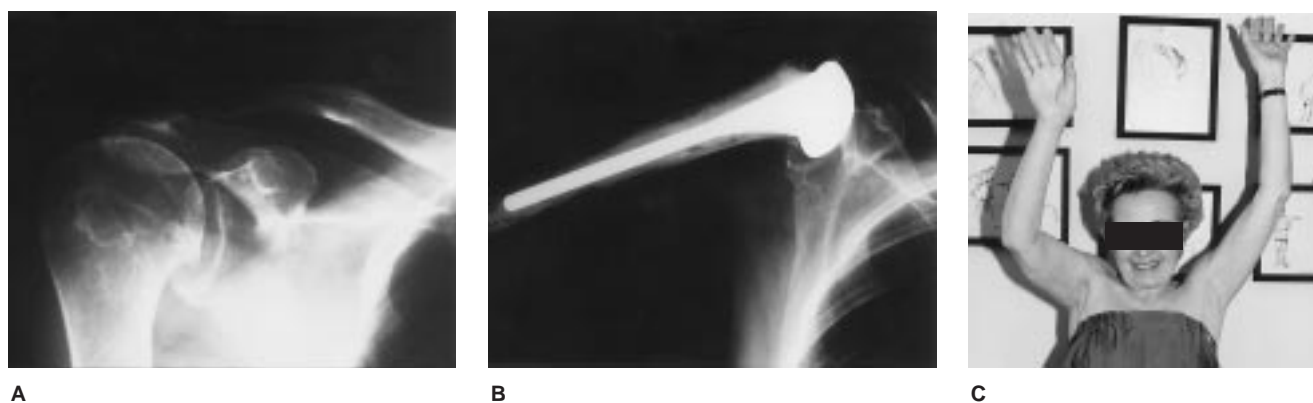


Fig. 7 A, Preoperative radiograph of a 73-year-old woman with RCTA treated with humeral hemiarthroplasty, glenoid burring, and superior transposition of the subscapularis. Radiograph (B) and clinical photograph (C) obtained 10 months after the procedure illustrate improved abduction.

abduction pillow can be used for the first 4 to 6 weeks. At approximately 3 weeks, pulley and internal-external rotation exercises on the pillow are started. When the bone graft across the superior aspect of the glenoid has united, active range of motion is initiated. Resisted strengthening is begun between 9 and 12 weeks.

In a small series compiled at our institution from 1987 to 1990, four types of surgical management were used to improve results in this group of patients: (1) bipolar prosthesis without cuff repair; (2) large-head hemiarthroplasty without cuff repair, (3) small-head hemiarthroplasty with subscapularis transposition, and (4) nonconstrained TSA with cuff repair. The results in 18 patients followed up for at least 2 years suggested that repair of large rotator cuff defects with subscapularis transposition and humeral hemiarthroplasty

with a relatively small head yielded the most reliable results.

Summary

The patient must realize that surgery will predictably provide pain relief, but that improvements in motion and strength are less predictable. The functional result will depend on the condition of the rotator cuff and deltoid muscle. The results are nearly always inferior to those that can be obtained with conventional prosthetic arthroplasty in shoulders with functionally intact cuffs.

A concerted effort must be made to repair the rotator cuff defect, resurface the arthritic humerus (hemiarthroplasty), and smooth the arthritic glenoid with a burr. Humeral hemiarthroplasty avoids the complications of glenoid loosening and is an attractive alternative to arthrodesis, resection arthroplasty,

constrained TSA, and semiconstrained TSA. The coracoacromial arch should be preserved and functionally intact to reduce the risk of anterosuperior subluxation. Care should be taken not to "overstuff" the glenohumeral joint with prosthetic components. When patients report considerably reduced internal rotation because of soft-tissue contracture, subscapularis lengthening or medialization or both are necessary to restore anterior and posterior rotator cuff balance. With the less stringent criteria of Neer's limited-goals rehabilitation, approximately 80% to 90% of patients treated with humeral hemiarthroplasty can have satisfactory results.^{3,8}

Glenohumeral arthrodesis is a salvage procedure when other surgical measures have failed. It is also a viable option for patients who have undergone multiple operations and for patients with deltoid muscle deficiency.

References

1. Neer CS II, Craig EV, Fukuda H: Cuff-tear arthropathy. *J Bone Joint Surg Am* 1983;65:1232-1244.
2. Williams GR Jr, Rockwood CA Jr: Massive rotator cuff defects and glenohumeral arthritis, in Friedman RJ (ed): *Arthroplasty of the Shoulder*. New York: Thieme Medical Publishers, 1994, pp 204-214.
3. Matsen FA III, Arntz CT, Harryman DT II: Rotator cuff tear arthropathy, in Bigliani LU (ed): *Complications of Shoulder Surgery*. Baltimore: Williams & Wilkins, 1993, pp 44-58.
4. Lohr JF, Cofield RH, Uhthoff HK: Glenoid component loosening in cuff tear arthropathy [abstract]. *J Bone Joint Surg Br* 1991;73(suppl 2):106.
5. Hawkins R, Bell RH, Jallay B: Total shoulder arthroplasty. *Clin Orthop* 1989;242:188-194.
6. Franklin JL, Barrett WP, Jackins SE, Matsen FA III: Glenoid loosening in total shoulder arthroplasty: Association with rotator cuff deficiency. *J Arthroplasty* 1988;3:39-46.
7. Pollock RG, Deliz ED, McIlveen SJ, Flatow EL, Bigliani LU: Prosthetic replacement in rotator cuff-deficient shoulders. *J Shoulder Elbow Surg* 1992; 1:173-186.
8. Swanson AB, Swanson GG: Bipolar shoulder arthroplasty, in Friedman RJ (ed): *Arthroplasty of the Shoulder*. New York: Thieme Medical Publishers, 1994, pp 265-280.
9. Neer CS II, Watson KC, Stanton FJ: Recent experience in total shoulder replacement. *J Bone Joint Surg Am* 1982;64:319-337.
10. Cofield RH: Total shoulder arthroplasty with the Neer prosthesis. *J Bone Joint Surg Am* 1984;66:899-906.
11. Marmor L: Hemiarthroplasty for the rheumatoid shoulder joint. *Clin Orthop* 1977;122:201-203.
12. Halverson PB, Cheung HS, McCarty DJ, Garancis JC, Mandel N: "Milwaukee shoulder": Association of microspheroids containing hydroxyapatite crystals, active collagenase, and neutral protease with rotator cuff defects—II. Synovial fluid studies. *Arthritis Rheum* 1981;24:474-483.
13. Halverson PB, Carrera GF, McCarty DJ: Milwaukee shoulder syndrome: Fifteen additional cases and a description of contributing factors. *Arch Intern Med* 1990;150:677-682.
14. Burkhart SS: A unified biomechanical rationale for the treatment of rotator cuff tears: Debridement versus repair, in Burkhead WZ Jr (ed): *Rotator Cuff Disorders*. Baltimore: Williams & Wilkins, 1996, pp 293-312.
15. Klimaitis A, Carroll G, Owen E: Rapidly progressive destructive arthropathy of the shoulder: A viewpoint on pathogenesis. *J Rheumatol* 1988;15: 1859-1862.
16. Dieppe P, Watt I: Crystal deposition in osteoarthritis: An opportunistic event? *Clin Rheum Dis* 1985;11:367-392.
17. Campion GV, McCrae F, Alwan W, Watt I, Bradfield J, Dieppe PA: Idiopathic destructive arthritis of the shoulder. *Semin Arthritis Rheum* 1988; 17:232-245.
18. Cofield RH: Degenerative and arthritic problems of the glenohumeral joint, in Rockwood CA Jr, Matsen FA III

- (eds): *The Shoulder*. Philadelphia: WB Saunders, 1990, vol 2, pp 678-749.
19. Cofield RH, Briggs BT: Glenohumeral arthrodesis: Operative and long-term functional results. *J Bone Joint Surg Am* 1979;61:668-677.
 20. Arntz CT, Matsen FA III, Jackins S: Surgical management of complex irreparable rotator cuff deficiency. *J Arthroplasty* 1991;6:363-370.
 21. Laurence M: Replacement arthroplasty of the rotator cuff deficient shoulder. *J Bone Joint Surg Br* 1991;73:916-919.
 22. Barrett WP, Franklin JL, Jackins SE, Wyss CR, Matsen FA III: Total shoulder arthroplasty. *J Bone Joint Surg Am* 1987;69:865-872.
 23. Lee DH, Niemann KMW: Bipolar shoulder arthroplasty. *Clin Orthop* 1994;304:97-107.
 24. Arntz CT, Jackins S, Matsen FA III: Prosthetic replacement of the shoulder for the treatment of defects in the rotator cuff and the surface of the glenohumeral joint. *J Bone Joint Surg Am* 1993;75:485-491.
 25. Williams GR Jr, Rockwood CA Jr: Hemiarthroplasty in rotator cuff-deficient shoulders. *J Shoulder Elbow Surg* 1996;5:362-367.
 26. Wiley AM: Superior humeral dislocation: A complication following decompression and debridement for rotator cuff tears. *Clin Orthop* 1991; 263:135-141.
 27. Engelbrecht E, Heinert K: More than ten years' experience with unconstrained shoulder replacement, in Kölbl R, Helbig B, Blauth W (eds); Telger TC (trans): *Shoulder Replacement*. Berlin: Springer-Verlag, 1987, pp 85-91.
 28. Field LD, Dines DM, Zabinski SJ, Warren RF: Hemiarthroplasty of the shoulder for rotator cuff arthropathy. *J Shoulder Elbow Surg* 1997;6:18-23.
 29. Codd TP, Flatow EL: Anterior acromioplasty, tendon mobilization, and direct repair of massive rotator cuff tears, in Burkhead WZ Jr (ed): *Rotator Cuff Disorders*. Baltimore: Williams & Wilkins, 1996, pp 323-334.
 30. Warner JJP, Krushell RJ, Masquelet A, Gerber C: Anatomy and relationships of the suprascapular nerve: Anatomical constraints to mobilization of the supraspinatus and infraspinatus muscles in the management of massive rotator-cuff tears. *J Bone Joint Surg Am* 1992;74:36-45.
 31. Bigliani LU, Cordasco FA, McIlveen SJ, Musso ES: Operative repair of massive rotator cuff tears: Long-term results. *J Shoulder Elbow Surg* 1992;1: 120-130.
 32. Codd TP, Pollock RG, Flatow EL: Prosthetic replacement in the rotator cuff-deficient shoulder. *Techniques Orthop* 1994;8:174-183.
 33. Randelli M, Gambrioli PL: Glenohumeral osteometry by computed tomography in normal and unstable shoulders. *Clin Orthop* 1986;208: 151-156.
 34. Kessel L: The transacromial approach for rotator cuff rupture, in Bayley J, Kessel L (eds): *Shoulder Surgery*. New York: Springer-Verlag, 1982, pp 39-44.